

Axillobifemoral Bypass Graft: A Student Dissection Experience

Jason D. Matakas,^{1*} Keara English,^{1*} Katherine Allyn,^{1*} Diane Algava,^{1*} Ruth Howe, MS,² Priti L. Mishall, MD,¹ and Sherry A. Downie, PhD,^{1,3}

¹ Department of Anatomy and Structural Biology, Albert Einstein College of Medicine, Bronx, NY.

² Department of Cell Biology, Albert Einstein College of Medicine, Bronx, NY.

³ Department of Physical Medicine and Rehabilitation, Albert Einstein College of Medicine, Bronx, NY.

* These authors contributed equally to this work.

As first-year medical students, we were excited, but nervous, to start the anatomy course. We were prepared to dedicate ourselves to the physical demands of dissection, and the hours of memorizing names and relations of countless anatomic features. We expected to leave the anatomy course with a comprehensive understanding of the human body that we would apply to our future studies and careers. We were not prepared, however, for the experience we had with our cadaver, Lucy.* Lucy was a small woman, but as we learned, she had endured a lot, physically and medically, in her 83 years of life. She had a pacemaker. She had coronary artery disease and a

triple bypass procedure. She also had severe peripheral artery disease and had undergone at least one extraordinary surgical graft procedure to maintain blood flow into her lower extremities. The surprise of discovering a small piece of an axillobifemoral bypass graft and then continuing to uncover it, region by region, throughout the anatomy course, brought our dissection experience and our connection to Lucy to a more profound level than we could ever have anticipated.

*The name Lucy was chosen as a pseudonym to protect the identity of the cadaver.

GETTING TO KNOW LUCY

We first met Lucy on a Wednesday evening the week prior to the start of the Clinical and Developmental Anatomy course. Our meeting was facilitated by a kind physician who volunteered to introduce us, and by our second-year peer assistant. Being in the anatomy lab for the first time, in the presence of so many deceased, was an overwhelming experience. Our physician carefully guided us through an inspection of Lucy's frail body. We identified several scars that hinted about procedures she had undergone, but otherwise Lucy seemed to be in pretty good shape.

DISSECTION REPORT

A week later, as we removed the skin from Lucy's thorax, we found a pacemaker resting on her left pectoralis major muscle. However, there was significant atrophy of her right pectoralis major muscle, which did not make much sense to us since the pacemaker was on her left side. Then, we uncovered a large, red, tube-shaped "muscle" running down the lateral aspect of her right chest. Truthfully, we didn't know what we had uncovered, but compared with other cadavers in the lab, we knew it was unusual and we were intrigued. Faculty members visited our cadaver to help us identify our "muscle." They were also unsure of what it was. Other students had hypotheses of their own. One thought it might be Lucy's esophagus. Another thought it might be a ventricular-peritoneal shunt.

By the time we left the thorax and moved on to Lucy's abdomen, we knew the "muscle" was a tube—a bypass graft—but we didn't know its origin or termination. Although we wanted to dissect the whole structure at once, we were instructed to follow the dissection sequence as dictated in

the course outline. As we progressed through each dissection module, we gradually uncovered the shunt.

During the abdomen dissection we found another surprise: The graft split into two components. The first continued straight down into Lucy's right thigh. The second arched across her lower abdomen toward her left thigh. Nevertheless, we could not follow the grafts.

As we reached the end of the abdomen dissection, we discovered that Lucy had an abdominal aortic aneurysm immediately proximal to the bifurcation of the aorta (Figure 1A, blue arrow). Inside the aorta was a large clot and the aortic walls were covered with plaque, as were the walls of the common iliac arteries. These indications of aortoiliac disease explained why the graft was designed to perfuse both limbs. At this point, one of the instructors from another lab visited our table and identified the tube as an axillobifemoral bypass graft (AXbiFBG). He briefly explained the procedure, and told us that he had rarely seen it in patients and had never seen one in a cadaver.

Throughout our dissection of Lucy, we identified evidence of vascular problems. In the thorax, a triple coronary bypass procedure had been performed and the heart was significantly enlarged. In the abdomen, in addition to the aortic aneurysm and plaque, we found a filter in the inferior vena cava (Figure 1A, green arrow). Despite evidence of severe vascular problems, Lucy's legs and feet appeared to be generally healthy and well-perfused, i.e. there was no ulceration or discoloration of the skin (Figure 1B). Thus, the AXbiFBG seemed to have successfully maintained Lucy's lower limb circulation.

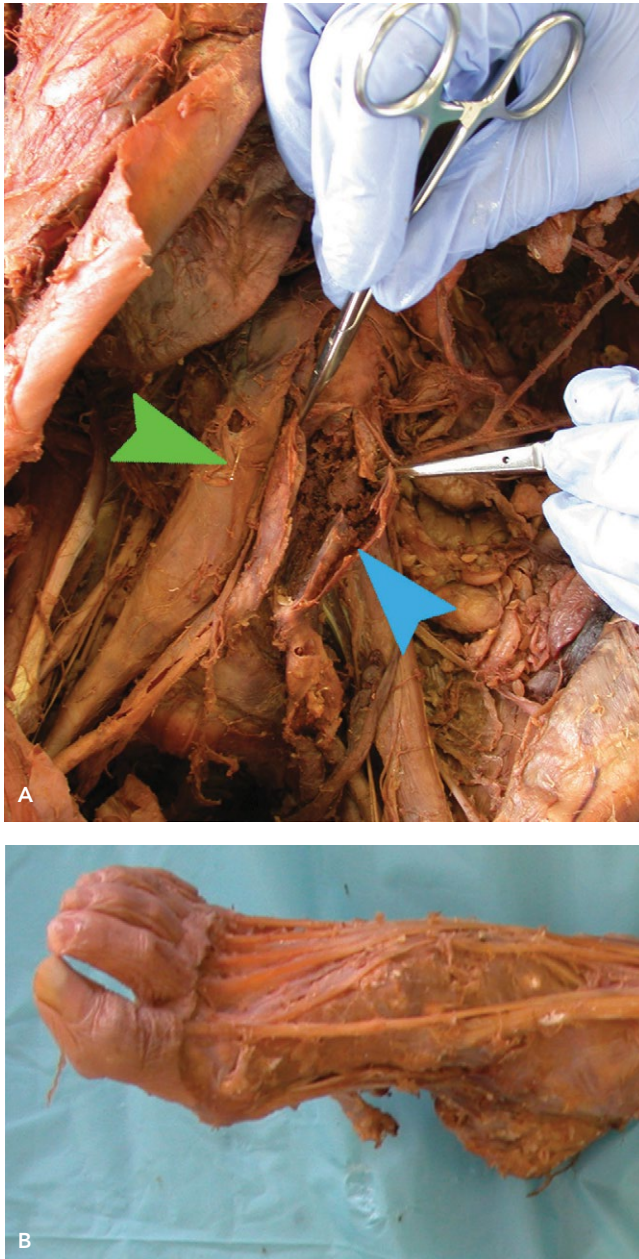

Figure 1 | A. Abdominal aortic aneurysm incised. Note the clot that extends bilaterally into the common iliac arteries (blue arrow). Inferior vena cava filter (green arrow). B. Right foot demonstrates no skin ulcers or discoloration indicating that there was adequate perfusion the limbs. Left foot was the same (not shown).

Before we could perform a detailed exploration of the proximal and distal portions of the graft, we had to complete dissection of the head and neck. In the meantime, we consulted the literature to find out more about AXbiFBG procedures. We learned that Lucy's graft was classified as an extra-anatomic bypass, in which the graft remains external to the body cavities in a tunnel created in the subcutaneous tissue. Extra-anatomic bypass procedures are indicated in elderly patients with significant limb ischemia, severe obstructive pulmonary disease, severe coronary artery dis-

ease, or chronic kidney disease (Mannick and Nabseth, 1968). Although we do not know when Lucy's graft was placed, we did find evidence of coronary artery disease as well as peripheral artery disease, perhaps explaining her candidacy for this extra-anatomic procedure.

We eagerly awaited the limb dissection modules so we could trace the remaining components of the graft.

By the time we reached the upper limb module, our dissection skills had improved significantly. Finally, we were able to follow the graft back to Lucy's right axillary artery, and demonstrate that some of the components of her medial brachial plexus were tangled around the proximal portion of the graft. According to Hoffman and Elliott (1987), in 62% of individuals the medial pectoral nerve (a branch of the medial cord of the brachial plexus) innervates the lower half or two-thirds of the pectoralis major muscle. Dissection of the pectoralis major and/or pectoralis minor muscle during the AXbiFBG procedure (Sauvage and Wood, 1966) may consequently injure the medial pectoral nerve. Although we did not trace it specifically, this was most likely the cause of atrophy of the costal portion of Lucy's right pectoralis major muscle.

During the lower limb dissection, we traced the graft into both of Lucy's femoral arteries. The vertical portion of the graft (Figure 2A) extended from her right axillary artery (Figure 2B) down to her right femoral artery. The horizontal portion of the graft extended from the right femoral graft, across her abdomen just superior to the pubic bone, to her left femoral artery (Figure 2C). At last we had uncovered the entire graft, and concluded a very satisfying experience. Our ability to at last observe the graft in its entirety made us all the more curious about the history and details of the AXbiFBG, and motivated us to research and compose a brief historical review that is included in this issue of the journal (Mishall et al., 2016)

CONCLUDING REMARKS

Words cannot fully describe the impact that human cadaver dissection has on a student. Each day in the anatomy lab we made new discoveries about Lucy, and gained insight into the life of a person suffering from coronary and peripheral artery disease. In addition to learning a tremendous amount about the human body and several clinical procedures, we came to understand a great deal about ourselves through this process. With the help of our cadaver-patient, Lucy, we grew as individuals and as team members. Over the four-month anatomy course, every member of our team became attached to Lucy, and our last day with her was an emotional one. Unfortunately, we will never know all the details about her interesting medical history, but we sincerely hope that the AXbiFBG improved her quality of life and contributed to her happiness. We are very grateful to her and will forever be thankful for her courageous gift.

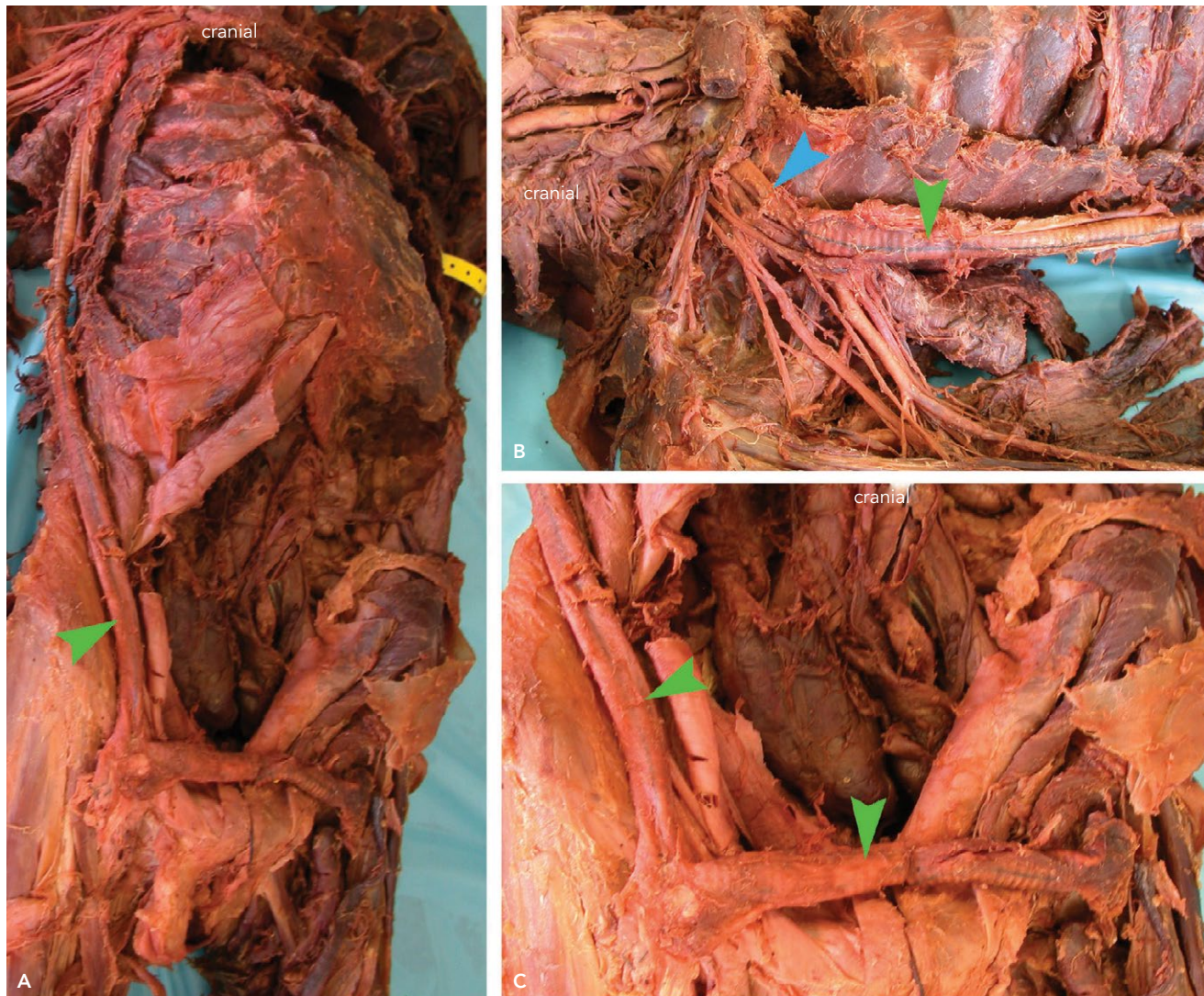


Figure 2 | Axillobifemoral bypass graft (Dacron®) in a cadaver-patient. A. Entire axillobifemoral graft *in situ*. B. Close up of the axillary graft. The axillofemoral graft (green arrows) originated in the right axillary artery (blue arrow) and tunneled between the pectoralis major muscle and thoracic wall. C. Close up of the bifemoral graft.

Corresponding Author: Priti L. Mishall, MD, PG CertMedEd, MBBS (priti.mishall@einstein.yu.edu).

Author Contributions: JDM, KE, KA, DA equally contributed to the literature review and manuscript preparation. RAH labeled the medical illustrations. PLM and SD edited, reviewed and provided guidance during the preparation of the manuscript.

Acknowledgements: RAH was supported by grants from the National Institutes of Health, T32 GM007288 and F30 HL 132613 during this study. The authors acknowledge and gratefully thank the individual whose body and tissues were used in this study for the advancement of physician education and patient care.

Disclosure: The authors have completed and submitted the ICMJE Form for Disclosure of Potential Conflicts of Interest. The authors have no conflicts of interest to report.

References

- Hoffman, G. W. and Elliott, L. F. (1987). The anatomy of the pectoral nerves and its significance to the general and plastic surgeon. *Ann Surg*, 205(5), 504–507.
- Mannick, J. A. and Nabseth, D. C. (1968). Axillofemoral bypass graft. A safe alternative to aortoiliac reconstruction. *N Engl J Med*, 278(9), 461–466.
- Matakas, J. D., English, K., Allyn, K., Algava, D., Howe, R. A., Mishall, P. L., Downie, S. A. (2016). Axillobifemoral bypass graft: a student dissection experience. *EJBM*, 31(1), 6–10.
- Sauvage, L. R. and Wood, S. J. (1966). Unilateral axillary bilateral femoral bifurcation graft: a procedure for the poor risk patient with aortoiliac disease. *Surgery*, 60(3), 573–577.